


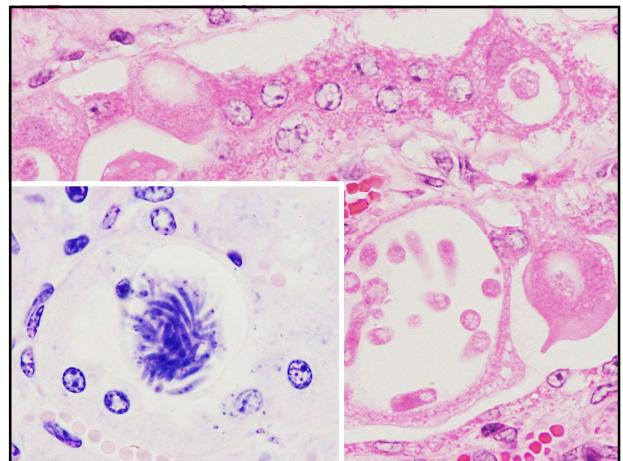
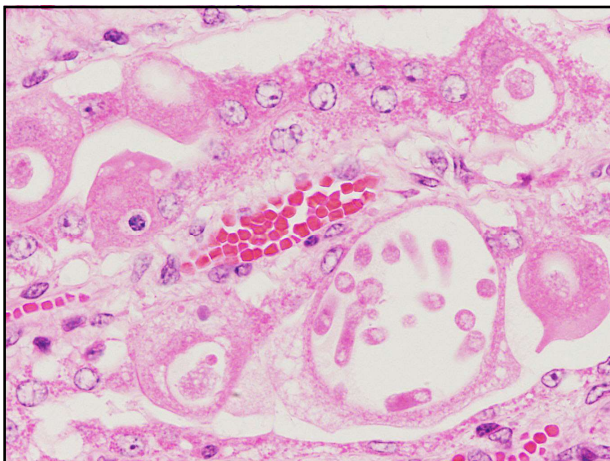
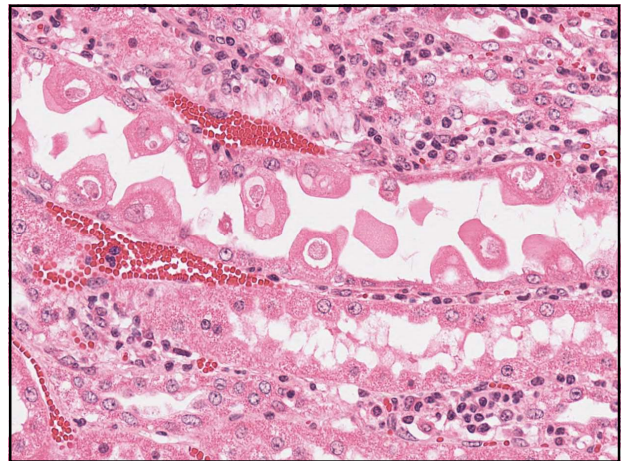
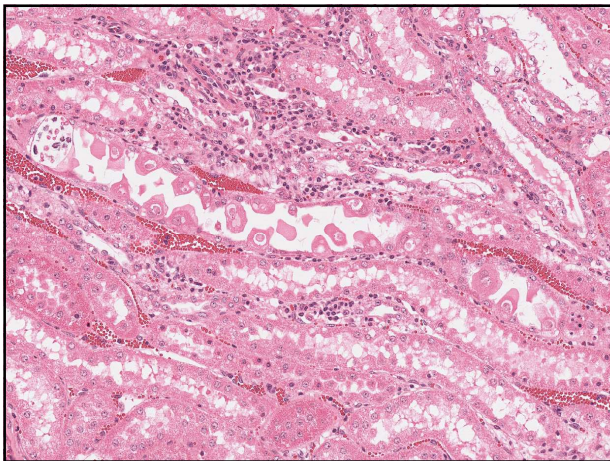
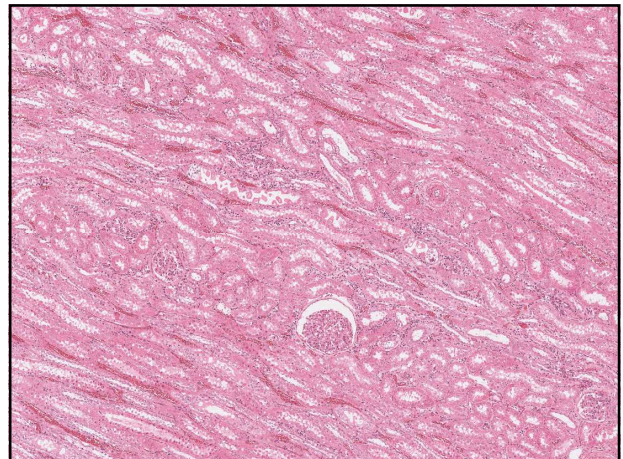
Fall 32 – Pferd




- Pferd, 11 Jahre alt

Vorbericht: seit 3-4 Monaten
Abmagerung, Harnstoffwert geringgradig
erhöht

09.03.2020 Stiftung Tierärztliche Hochschule Hannover
University of Veterinary Medicine Hannover, Germany 103

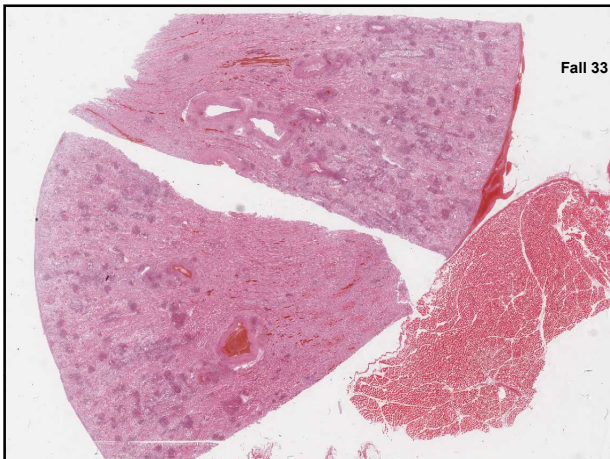
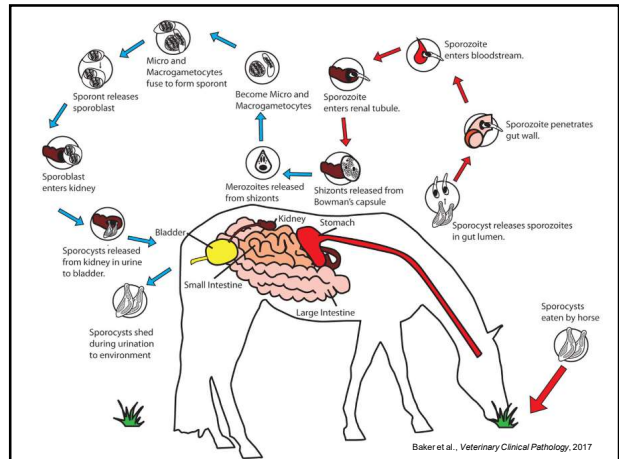


Fall 32 – Pferd




Morphologische Diagnose:
Lymphohistiozytäre interstitielle Nephritis mit tubulärer Degeneration und intraepithelialen protozoären Parasitenstadien

09.03.2020 109
Stiftung Tierärztliche Hochschule Hannover
University of Veterinary Medicine Hannover, Foundation



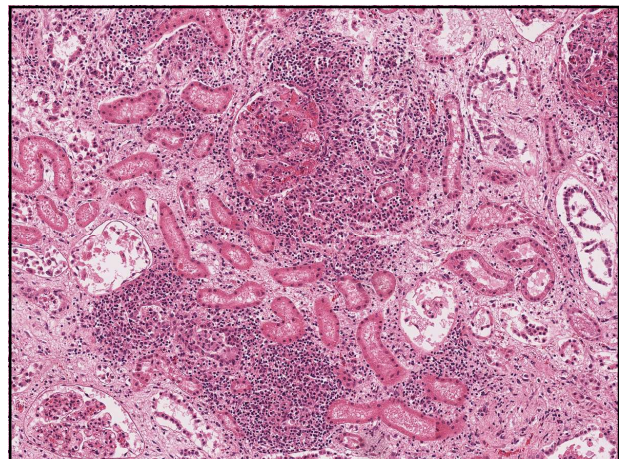
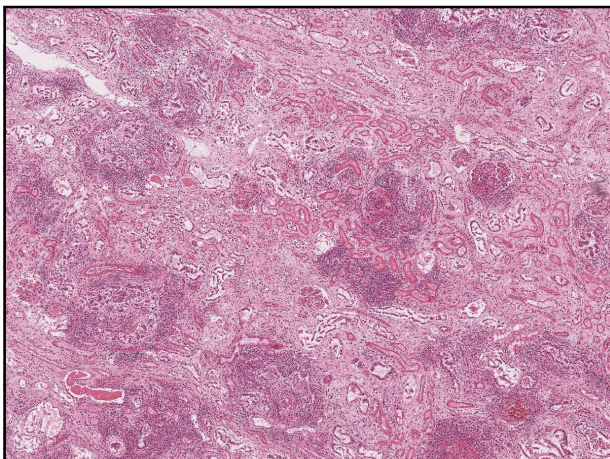
Fall 33 – Ziege

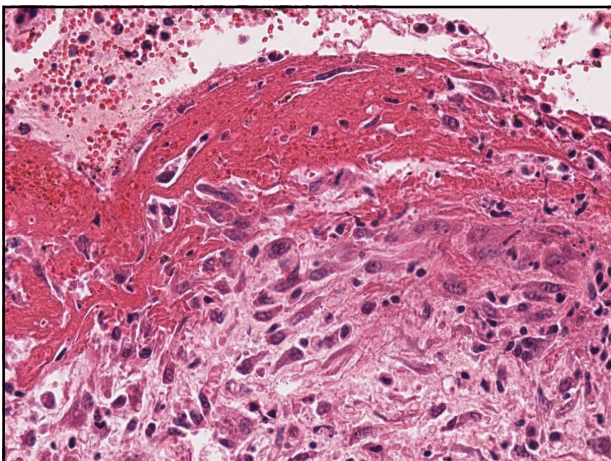
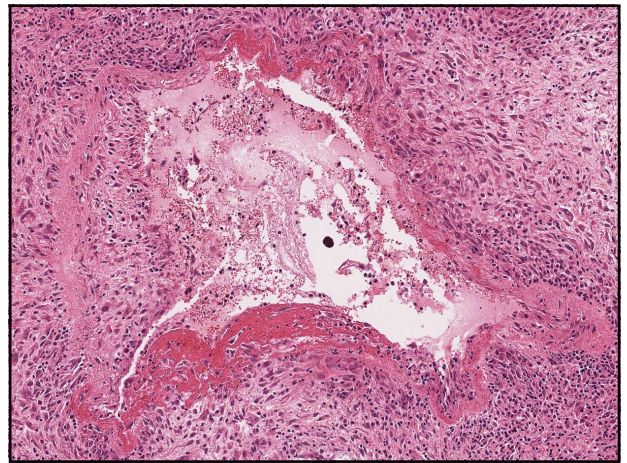
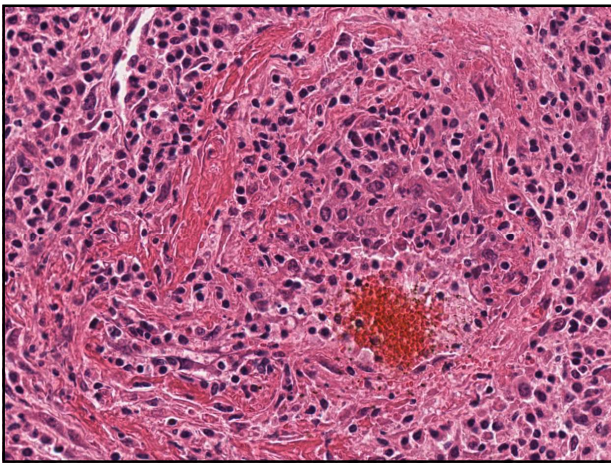
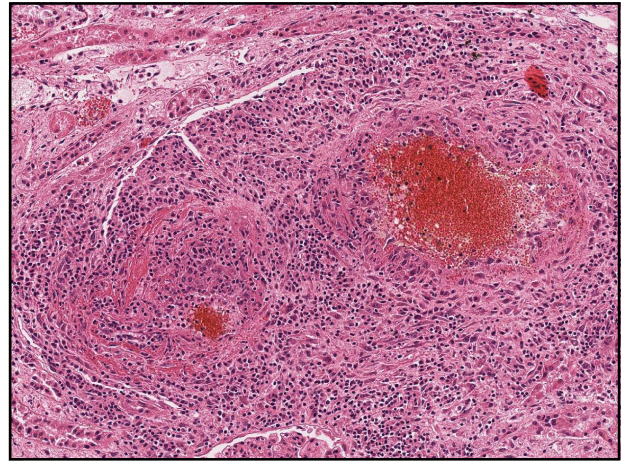
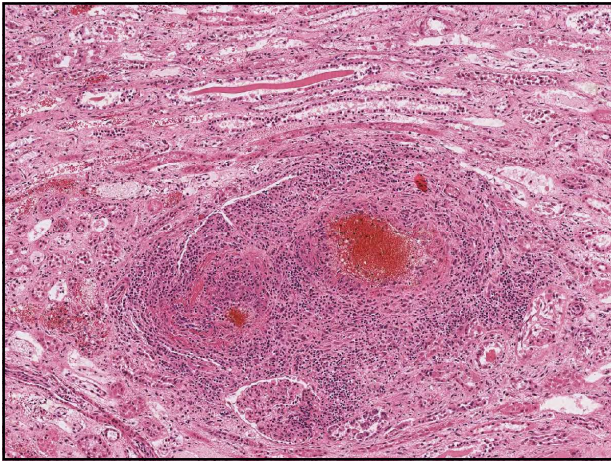


- Ziege, 7 Jahre alt


Vorbericht: ataktischer Gang, ZNS-Ausfallerscheinungen, ASTA, GLDH und Kreatinin erhöht

09.03.2020 112
Stiftung Tierärztliche Hochschule Hannover
University of Veterinary Medicine Hannover, Foundation






Fall 35 – Ziege



Morphologische Diagnose:
Lymphohistiozytäre interstitielle Nephritis
mit Vaskulitis und fibrinoider
Gefäßwandnekrose

09.03.2020 Stiftung Tierärztliche Hochschule Hannover
Fakultät für Veterinäre Medizin, Hannover, Deutschland 120

Fall 35 – weitere Befunde




Organ	Befund
Leber	Lymphohistiozytäre Vaskulitis mit fibrinoider Gefäßwandnekrose
Nieren	
Lymphknoten	
Milz	
Gehirn	
Retina	
Rete mirabile	

09.03.2020 121

Stifting Tierärztliche Hochschule Hannover
University of Veterinary Medicine Hannover, Foundation

Fall 35 – weitere Befunde



Tagebuch-Nr. / Reference-No. [REDACTED] Datum / Date 24.08.05

Entnahme / Sampling date 22.08.05

Tierart / Species Ziege/goat

Rasse / Breed

Tier-ID / Animal ID [REDACTED]

Unters.materi.al / Test material Vollblut; Organproben

Mit Hilfe der Polymerase Kettenreaktion (PCR) konnte Ovin Herpesvirus (OHV-2) nachgewiesen werden


Using polymerase chain reaction (PCR) ovine herpesvirus (OHV-2) could be detected

09.03.2020 122


Stifting Tierärztliche Hochschule Hannover
University of Veterinary Medicine Hannover, Foundation

Ovines Herpesvirus-2-Infektion bei Ziegen





Available online at www.sciencedirect.com



Veterinary Microbiology 134 (2007) 383–387

**veterinary
microbiology**

www.elsevier.com/locate/vetmic

Short communication

Malignant catarrhal fever-like lesions associated with ovine herpesvirus-2 infection in three goats

Björn Jacobsen^a, Kerstin Thies^b, Alexandra von Altrock^b,
Christine Förster^c, Matthias König^a, Wolfgang Baumgärtner^{a,b}

^aDepartment of Pathology, University of Veterinary Medicine Hannover, Bundesweg 47, D-30559 Hannover, Germany
^bUnit for Pigs, Small Ruminants, Avian, Medicine and Ambulatory Service, University of Veterinary Medicine Hannover,
 Bischofsholer Damm 15, D-30611 Hannover, Germany
^cInstitut of Virology, Faculty of Veterinary Medicine, Justus-Liebig-University Gießen, Friedberger Strasse 107,
 D-35392 Giessen, Germany

Received 18 December 2006; received in revised form 16 April 2007; accepted 23 April 2007

Abstract

This is the first description of malignant catarrhal fever-like lesions associated with ovine herpesvirus-2 (OHV-2) infection in goats with central nervous symptoms. The diagnosis was based on typical histological lesions characterized by systemic lymphohistiocytic and fibrinoid vasculitis and confirmed by polymerase chain reaction and subsequent phylogenetic analysis of the detected OHV-2 sequences.

© 2007 Elsevier B.V. All rights reserved.

09.03.2020 123

Stifting Tierärztliche Hochschule Hannover
University of Veterinary Medicine Hannover, Foundation